

# DermaCLIP<sup>®</sup>

## Transforming Wound Closure

Optimize Patient Outcomes with a  
Simplified Closure Solution

Photos of Use  
Across the Continuum of Care

A close-up photograph of a surgical incision on a patient's abdomen. The wound is closed with several white, rectangular adhesive strips (DermaCLIPs) applied in a row along the length of the incision. The surrounding skin is clean and the patient is wearing a blue hospital gown.

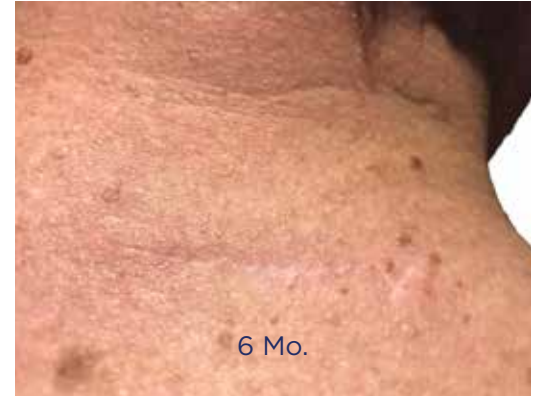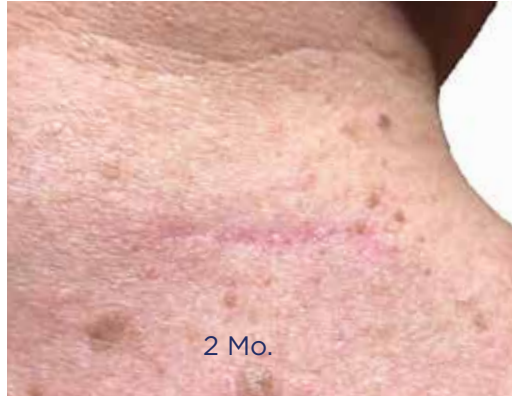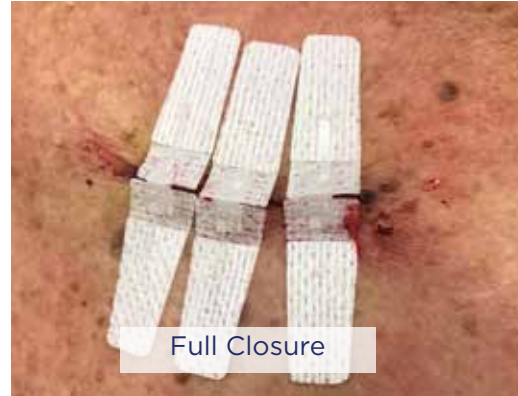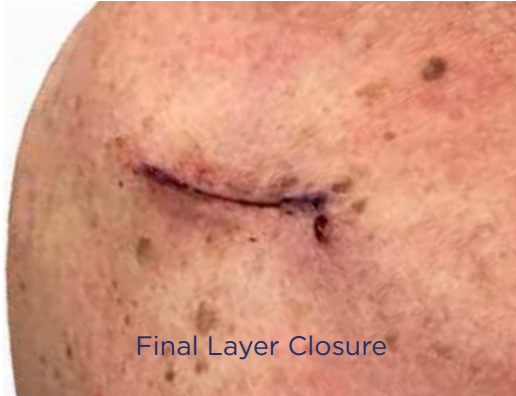ABDOMINOPLASTY

A photograph of a patient's forearm showing a traumatic laceration. The wound is closed with several white, rectangular adhesive strips (DermaCLIPs) applied in a row along the length of the incision. The surrounding skin shows signs of trauma, including bruising and smaller abrasions.

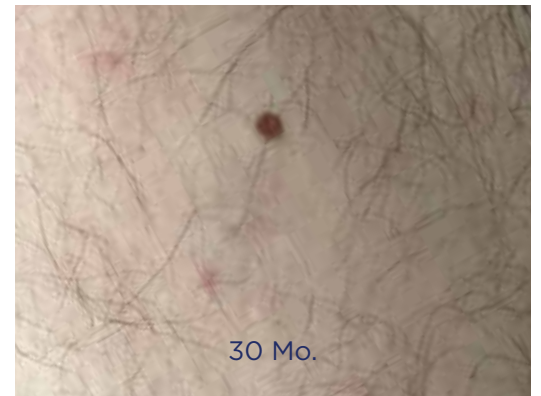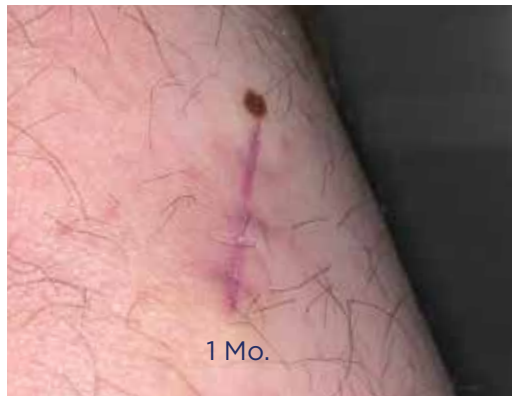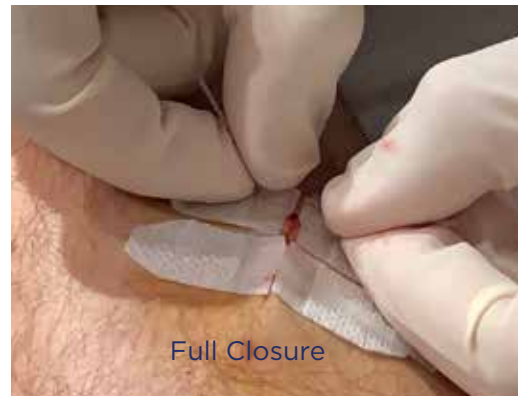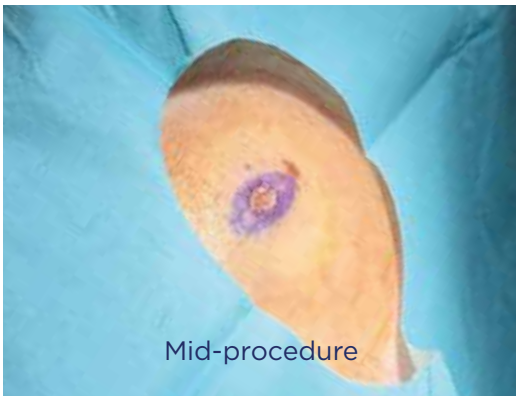
TRAUMATIC ARM LACERATION

# DERMATOLOGY (EXCISIONS & MOHS)

DermaClip provides skin closure without punctures, enabling great results without a plastic surgeon.

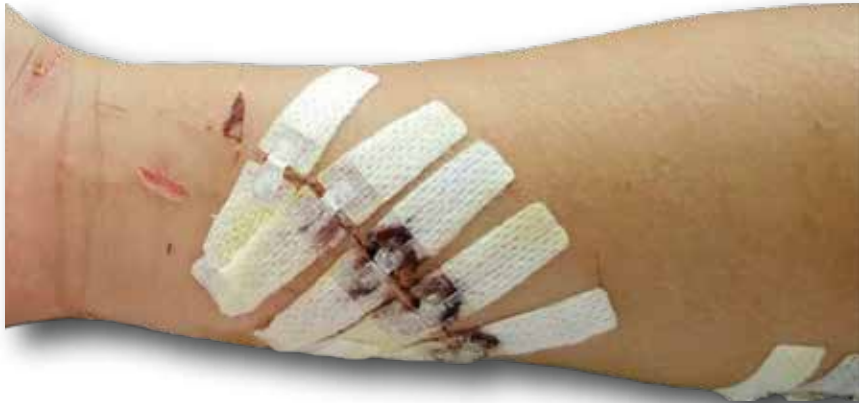

Above: Excision on 68 y.o. Patient  
Below: Excision on 36 y.o. Patient



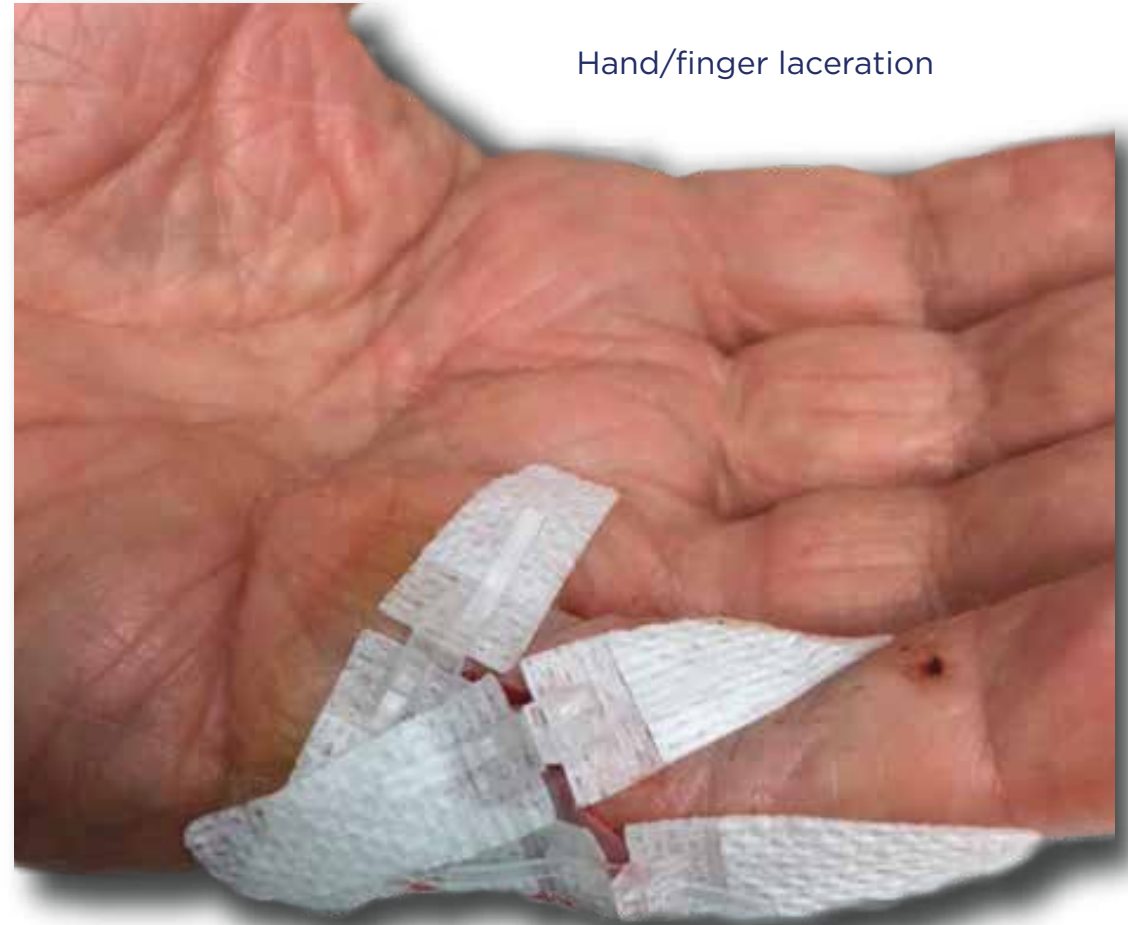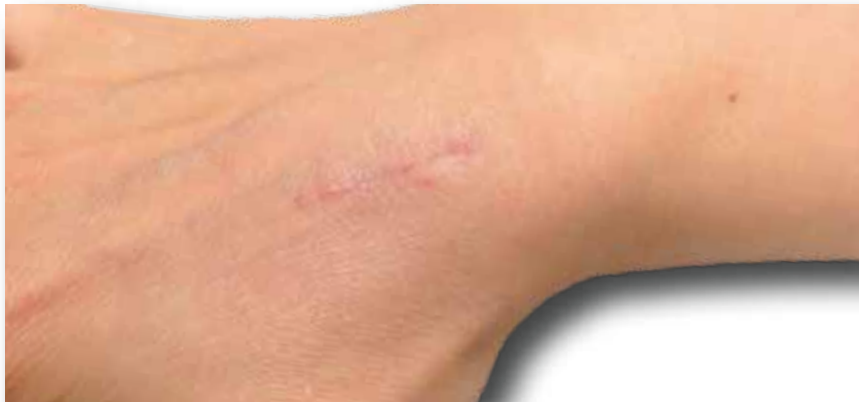# EMERGENCY DEPARTMENT & URGENT CARE

DermaClip provides optimal results for patients with lacerations and avoids the inconvenience to both patient & facility of the removal visits (e.g., sutures & staples)



Above: Traumatic Arm Laceration

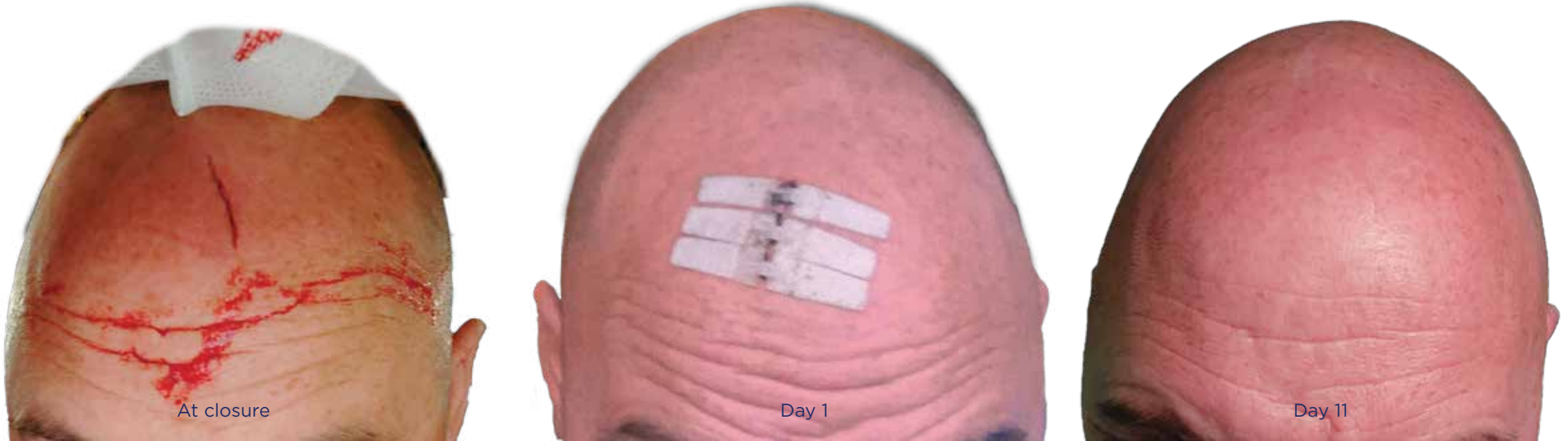Below: Wrist / hand closure, 2 mo. post-closure



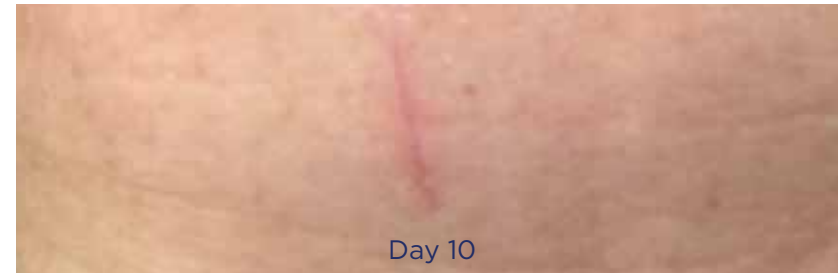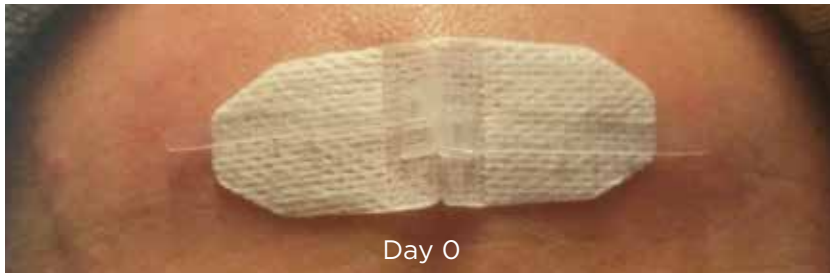Hand/finger laceration

# EMERGENCY DEPARTMENT, URGENT CARE & EMS

The ease of use allows DermaClip to be used off-site, wherever wounds need closure

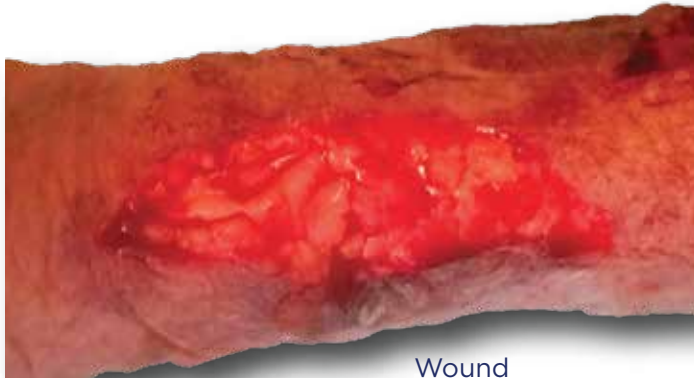


*Above: Male patient with head laceration | Closed by provider in wilderness  
Below: Male patient with forehead laceration | Closed by provider in wilderness*

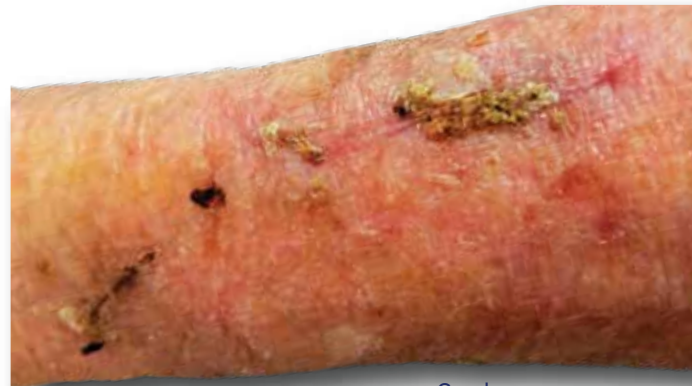

# FRAGILE SKIN (GERIATRIC, RADIATED, DIABETIC)

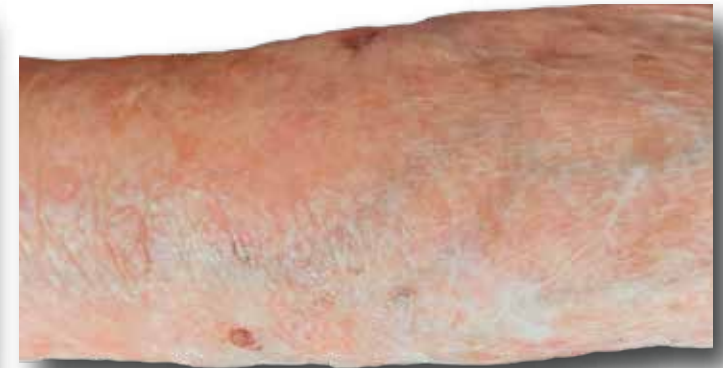Disperses wound tension on closure, enabling great results on patients with compromised skin quality.



Wound

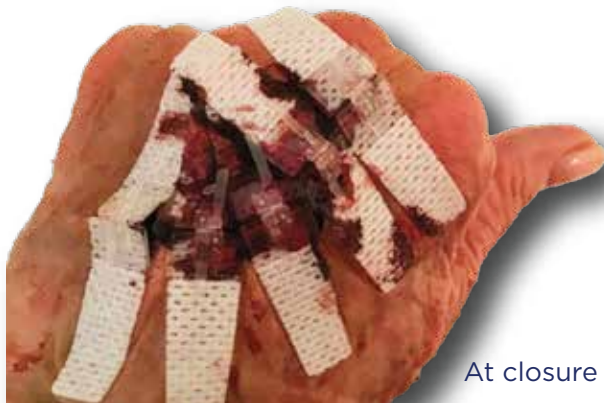

6 wks.

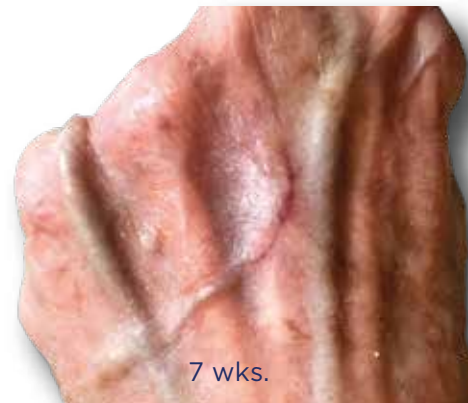

5 mo.

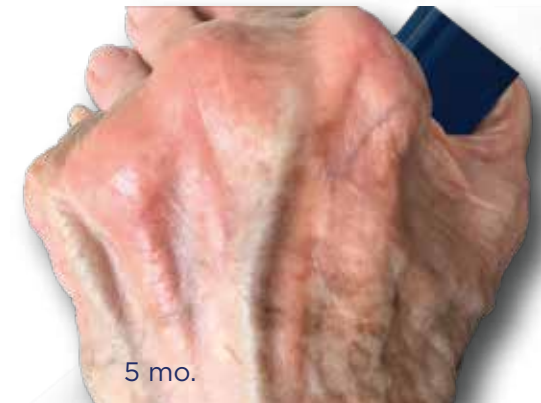*Above: 84-Year-Old | Traumatic Arm Laceration | Closed @ Home Visit  
Below: 79-year-old, Anticoagulated | Skin Flap, Bleeding for 24 Hours | Closed @ Home Visit*



At closure



7 wks.

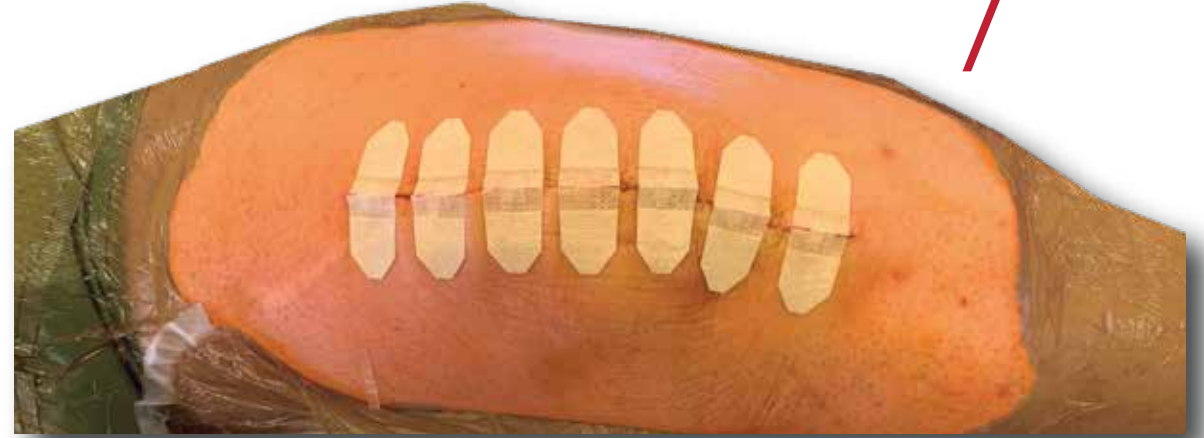

5 mo.

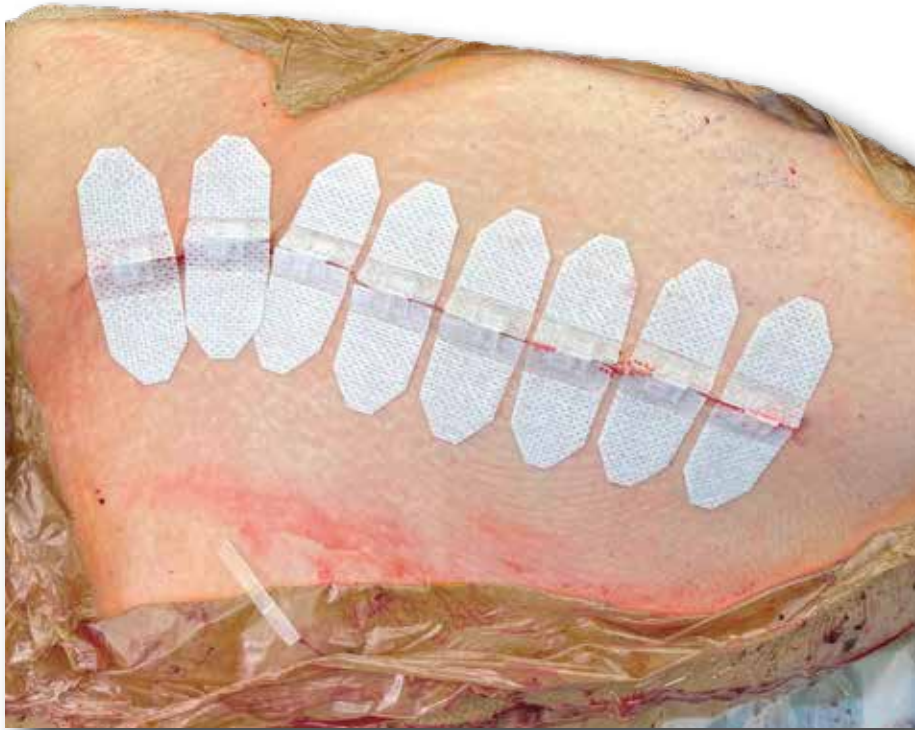
Peer-reviewed White Paper in Case Reports in Emergency Medicine

# ORTHOPAEDIC SURGERY

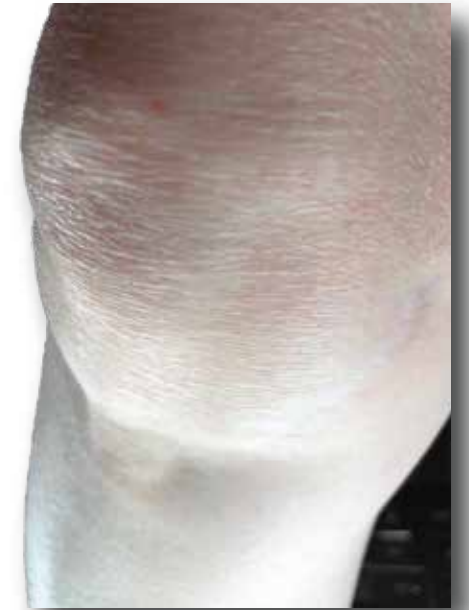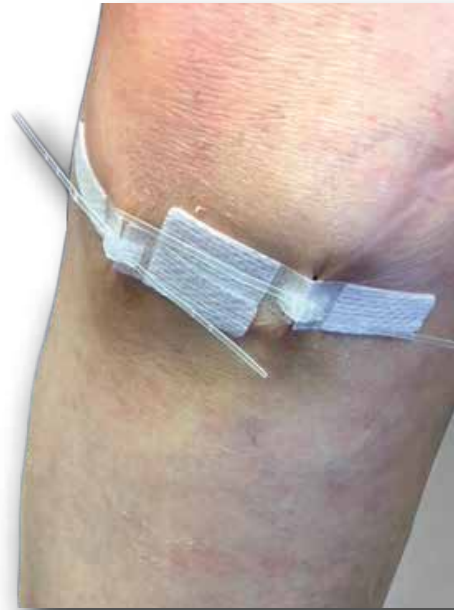Expedited closure in orthopaedic surgery, both open and minimally invasive, allows providers to see more patients without the scarring associated with staples.



Knee Arthroplasty (*above*), Knee Arthroscopy with Result (*below*)

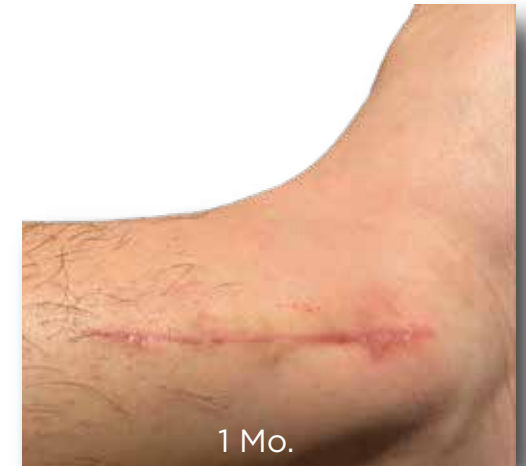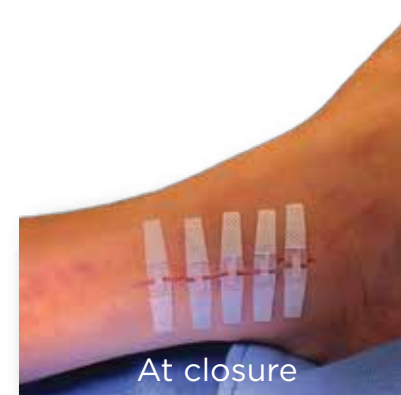

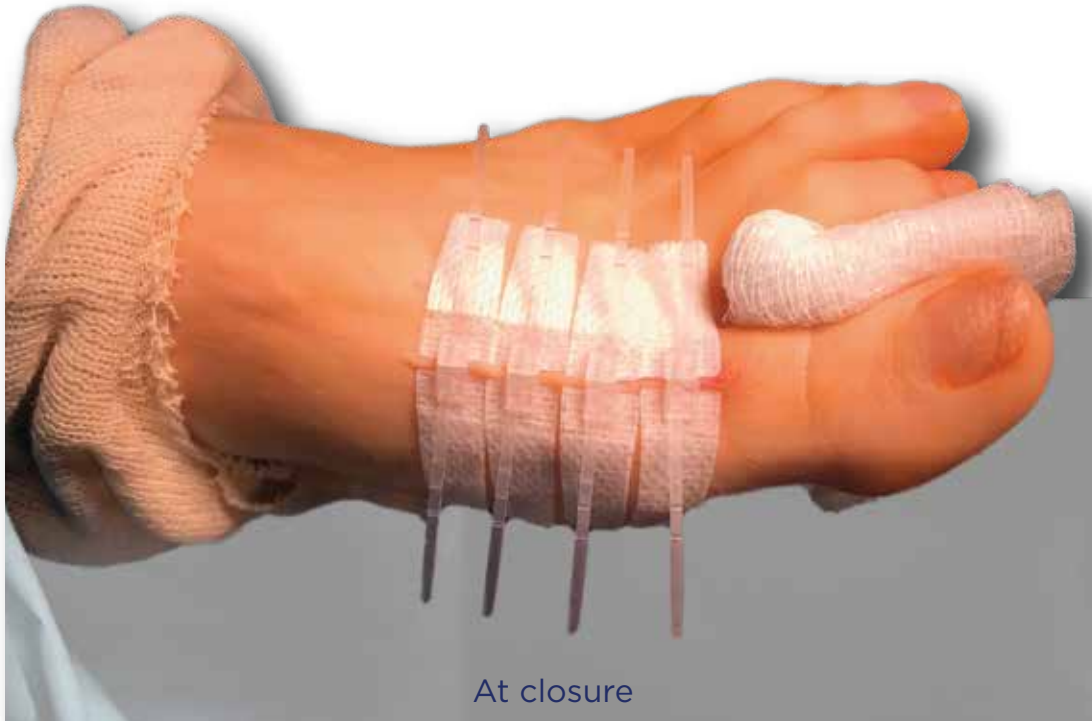
At closure

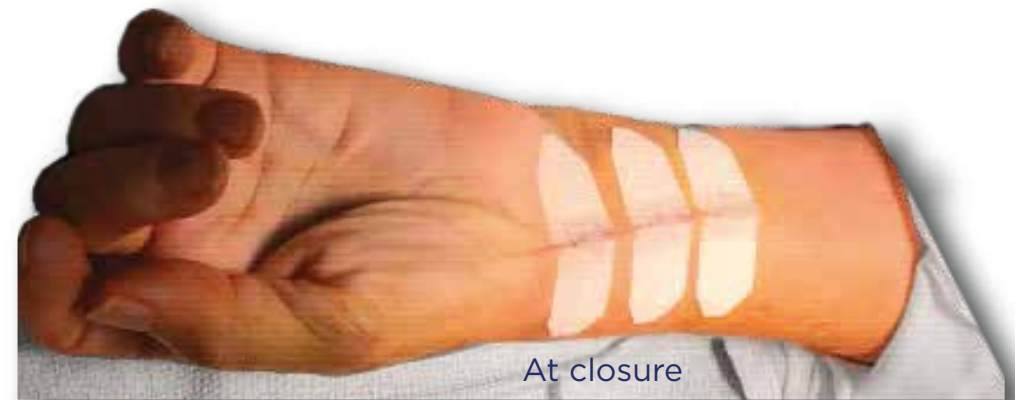

# ORTHOPAEDIC SURGERY (HAND, FOOT & ANKLE)

Reduced closure time in procedures utilizing a tourniquet can have enhanced benefits when eliminating a lengthy reperfusion cycle.

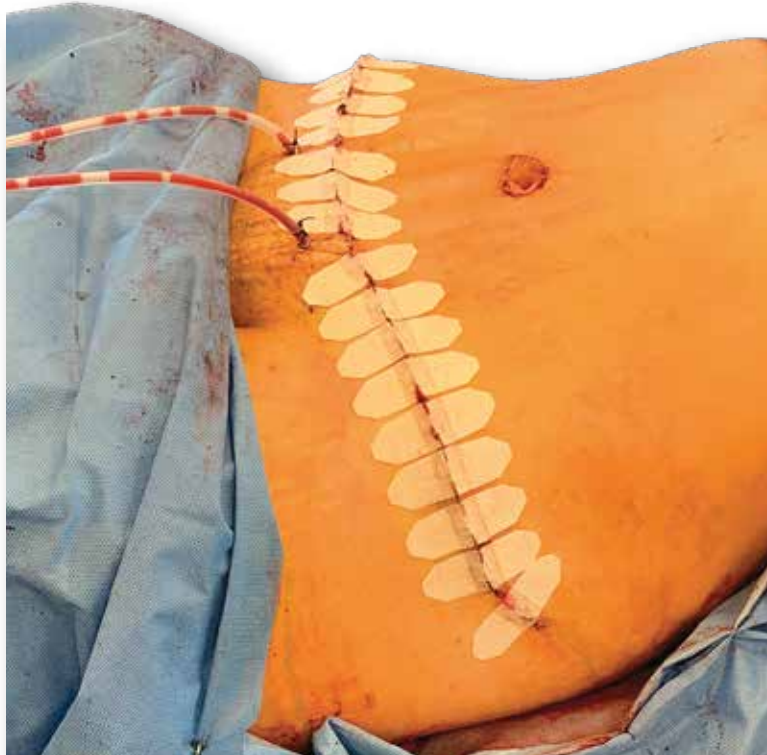

Ankle repair with result (*above*), Wrist surgery (*below*)



# PLASTIC SURGERY, ABDOMINOPLASTY

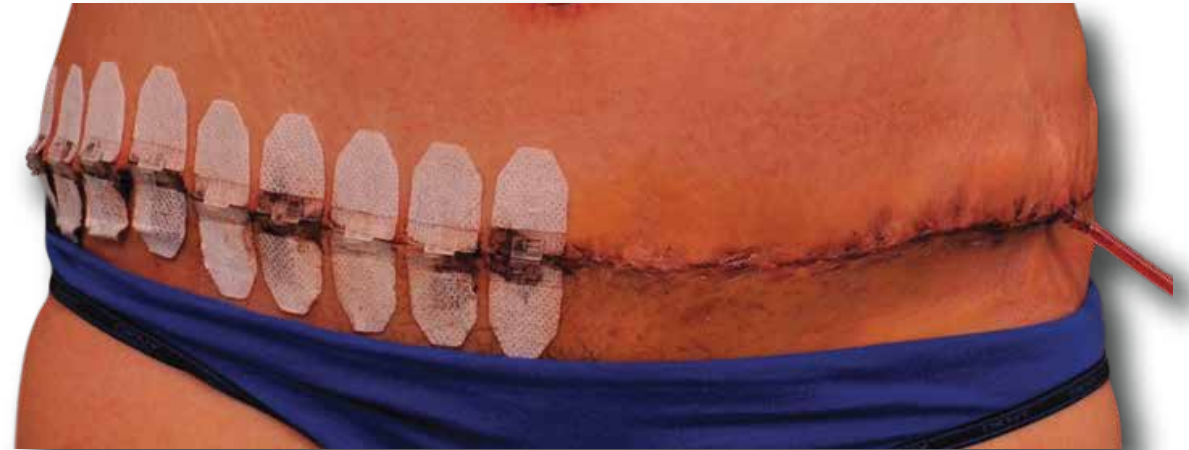Used by plastic surgeons across the US for final closure or for wound support, depending on the surgeon



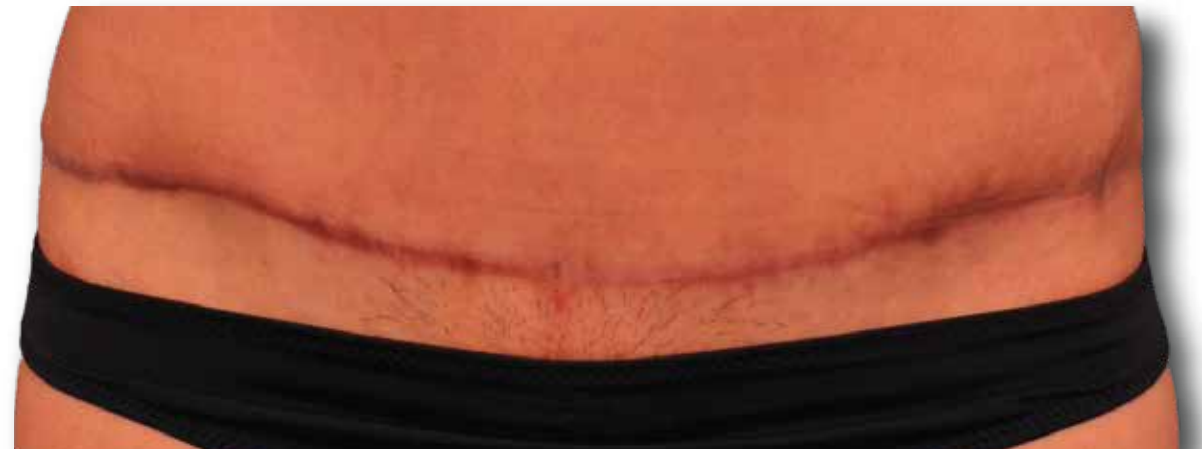At closure

## *Abdominoplasty Comparison Use Trial*

Half closed with DermaClip (all skin layers above fascia)  
Half with Sutures (3 layers of suturing above fascia)



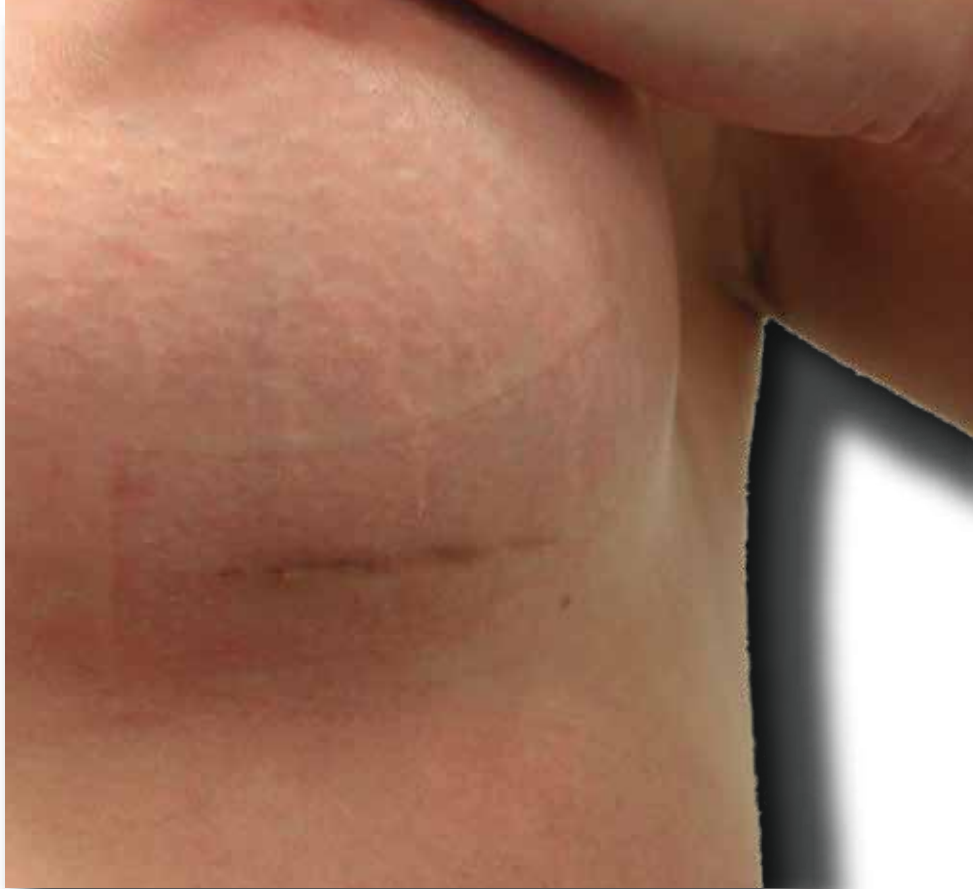5 days post-op (*above*), 4 month post-op (*below*)



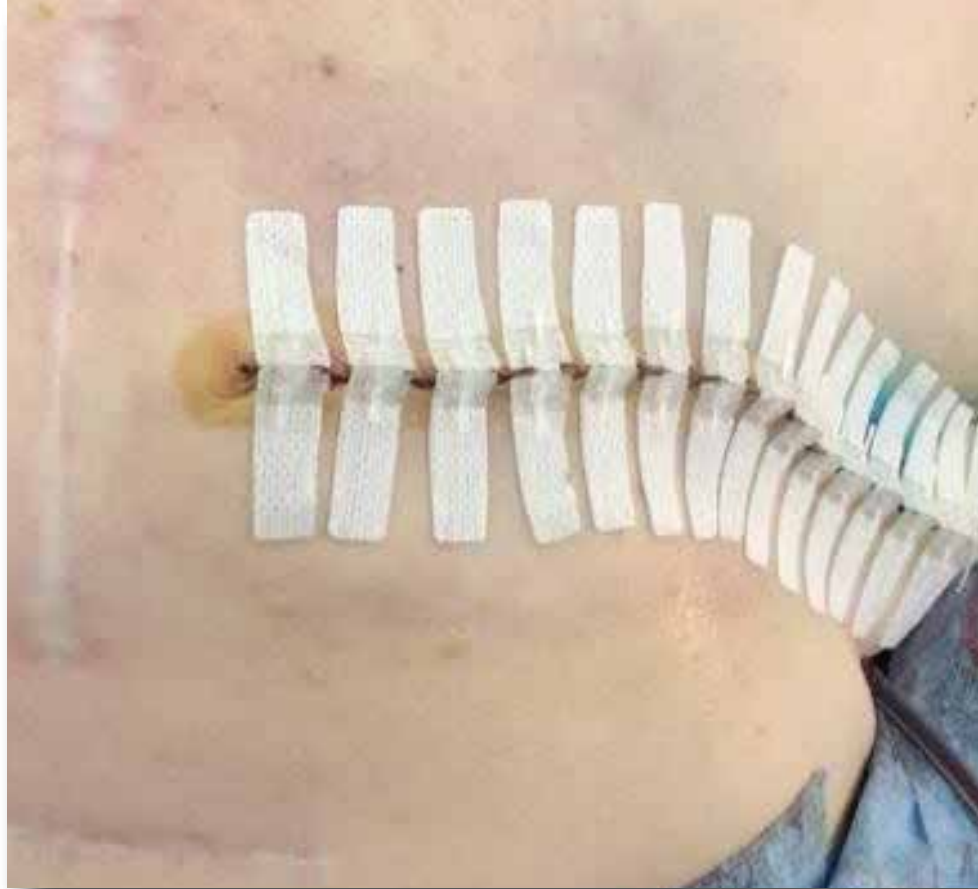


# PLASTIC SURGERY & REPAIR

DermaClip disperses tension while avoiding railroad-track scarring



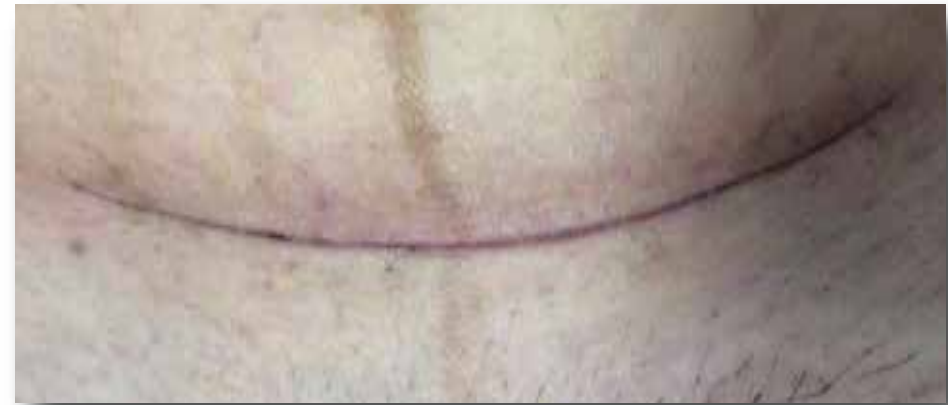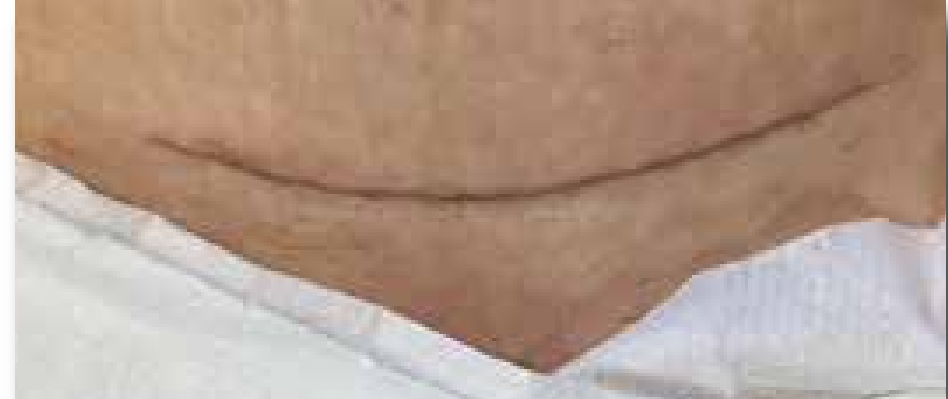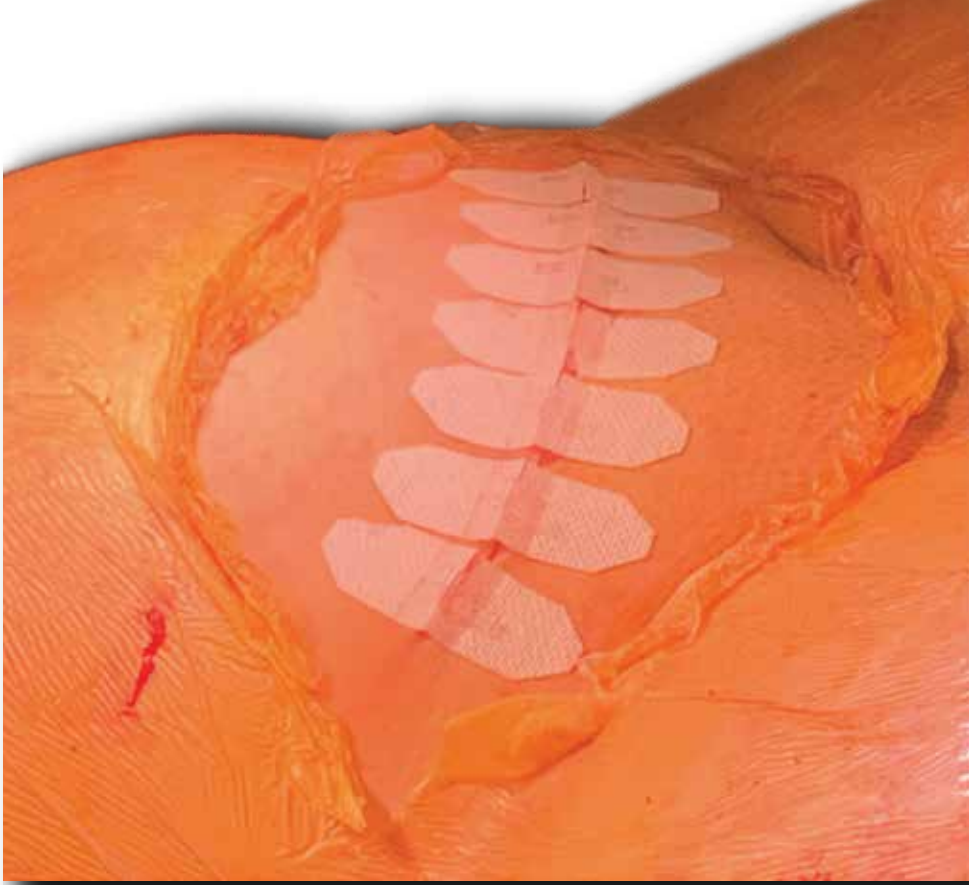Breast Augmentation @ 7 weeks



Mastectomy @ closure

# WOMEN'S HEALTH (C-SECTION)

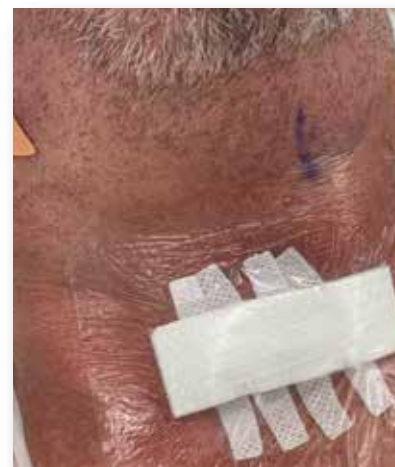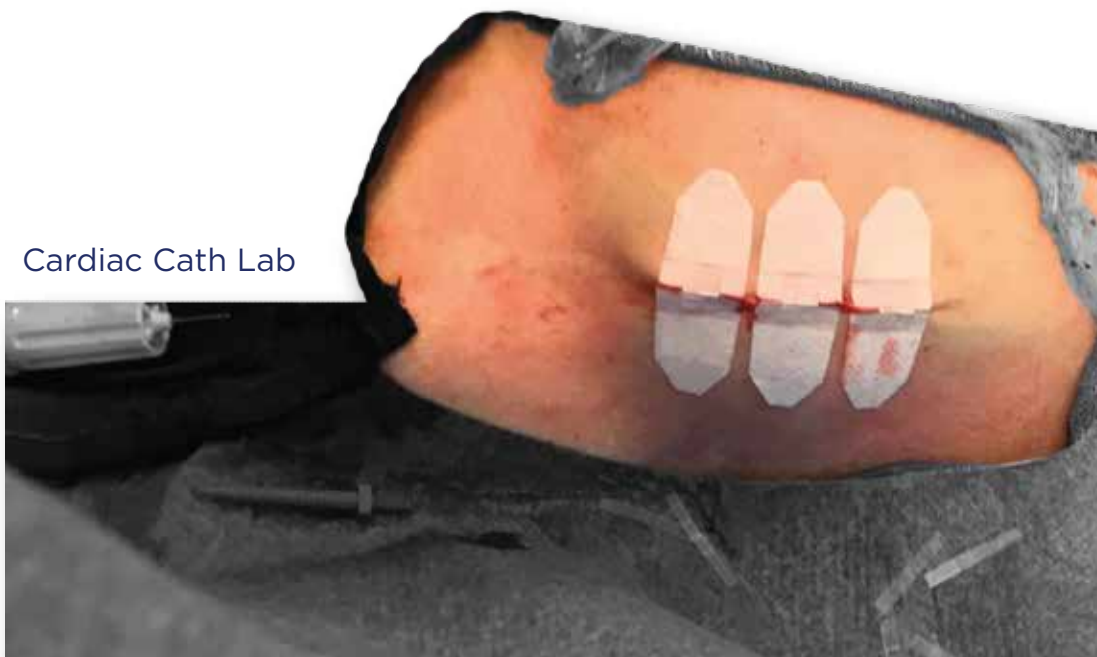DermaClip avoids the trauma of staples in closure of C-sections, an important benefits for patients



# OTHER USES

DermaClip facilitates wound closure wherever skin needs to be closed.

Cardiac Cath Lab



Spine, Cervical



Spine, MIS



[www.DermaClip.com](http://www.DermaClip.com)  
[info@DermaClip.com](mailto:info@DermaClip.com)  
+1 (713) 682-3185